

Ultrasonic Visualization of Excitation Wavefront Propagation in Heart Wall

心臓壁心筋の興奮伝播波面の超音波による可視化

Hiroshi Kanai^{1†} and Motonao Tanaka² (¹Grad. Schools of Eng. and Biomedical Eng., Tohoku Univ.; ²Professor Emeritus, Tohoku Univ.)
金井 浩^{1†}, 田中元直² (¹東北大 工/医工; ²東北大 名誉教授)

1. Introduction

Since polarization of cells does not occur in an infarcted myocardium resulting from coronary artery occlusion, electrocardiography, by which electrical potentials generated by cell polarization are measured, is an invaluable clinical tool for the diagnosis of a broad range of cardiac conditions. However, the regional properties of the myocardium cannot be obtained by electrocardiography. Clinical imaging tools (CT, tissue tagging MRI¹⁾, and conventional echocardiography^{2,3)} enable visualization of cross-sectional images, motion, and torsional deformation during contraction. However, they are restricted to static configurations or large and slow motion, and measurement of minute velocity waveforms occurring just after electrical excitation in the myocardium has not been realized.

We have previously found that pulsive vibration occurs just after electrical stimulation of the extracted papillary muscle of a rat⁴⁾. When the displacement or deformation, corresponding to the accumulation of velocity, is measured, the proximate response to the stimulation cannot be ascertained since its amplitude is too minute (about 30 μm in displacement and 0.5 mm/s in velocity). However, by applying a novel ultrasound-based noninvasive method^{5,6)} to human hearts, we were able to successfully measure the proximate response of the myocardium to electrical excitation⁷⁾. However, such measurement was limited to the two-dimensional (2D) plane corresponding to scanning of the ultrasonic beams. In the present study, the propagation of the proximate response to the electrical excitation just before the time of the R-wave (TR) of the electrocardiogram (ECG) was visualized in three-dimensional (3D) space for the first time in healthy subjects.

2. Method

By controlling a stepping motor with reference to the ECG, the ultrasound probe on the chest wall was rotated intermittingly by 7.2 degrees in each relaxation period during several successive

heartbeats, and the RF reflective wave in response to each ultrasound transmission was acquired on each of several 2D planes obtained by slicing the left ventricle (LV). The number of directions of transmission in each plane was restricted to 16 to maintain a high frame rate (500 Hz) in the modified conventional ultrasound equipment and thus minute velocity could be measured as waveforms⁶⁾. At all of about 10,000 points in the heart wall, the velocity waveforms toward the ultrasonic probe (origin O) on each fan-shaped ultrasound-scanning plane were simultaneously obtained, and their instantaneous phases of 40-Hz components were color-coded. By adjusting the times $\{T_R\}$ in the several heartbeats, the instantaneous 3D distribution of the phase was reconstructed at every 2 ms, precisely revealing the propagation of the velocity waves in the LV. The results were shown for the interior wall of the front hemisphere of the LV seen from the upper back of the heart. This novel method was applied to healthy subjects.

The achieved lower limit in the velocity measurement has been validated as being about 0.1 mm/s, which corresponds to 0.13 μm in displacement⁷⁾. The accuracy in the adjustment of the times $\{T_R\}$ was 0.2 ms, which is sufficiently smaller than the reconstructed interval (2 ms) of the 3D phase distributions.

3. In vivo Experimental Results

For a healthy subject, **Fig. 1** shows the results obtained consecutively at every 7.0 ms (= 2.3 ms \times 3 frames) from 42 ms prior to T_Q . The results were shown for the interior wall of the LV free wall and the right ventricular side of the IVS seen from the upper right of the heart. **Figures 1(7)** and **1(15)** correspond to T_Q and T_R , respectively.

(a) The red component was generated at the apical side of the anterior wall, which was close to the root of the musculus papillaris posterior (**Fig. 1(1)**), and propagated counterclockwise to the whole LV at a speed of 0.7 m/s (**Figs. 1(2)-(16)**).

(b) From the radiation time of the first heart sound (**Fig. 1(17)**), a yellow-green component was generated at the apical side of the IVS and

propagated upward to the base side along the IVS at a speed of 0.6 m/s (Figs. 1(18)-(33)).

(c) Finally, the red component became dominant again in the whole LV except at the root of the papillary muscle (Figs. 1(34)-(35)).

4. Discussion

For MRI, the temporal resolution is inevitably limited by the relaxation time (14-25 ms) of the tissue in response to the magnetic excitation⁸⁾, and the in-plane spatial resolution is 1.25×3 mm. The tissue Doppler imaging technique is restricted to static configurations or large motion (> 1 mm) with low frequency components (< 30 Hz) because the detectable amplitude is greater than the wavelength (400 μ m) and the temporal resolution is at most 16 ms. Therefore, it has been considered that there are no minute velocity components in the human heart walls, and none of conventional clinical imaging methodologies can detect minute velocity waveforms nor visualize myocardial dynamic properties with high temporal resolution of a few milliseconds⁶⁾.

The subtle dynamic response of the myocardium to the arrival of the electrical stimulation demonstrated by the novel echocardiography developed in the present study with a high temporal resolution of 2 ms shows great potential for noninvasive assessment of myocardial tissue damage due to heart failure and desynchronization due to fibrillation.

Acknowledgment

The author acknowledges the experimental contributions of Assoc. Prof. Hideyuki Hasegawa. The study was approved by the review committee of the Graduate School of Engineering, Tohoku University and the healthy subjects gave informed consent. This study was partly supported by a grant-in-aid for scientific research from the Ministry of Education, Culture, Sports, Science, and Technology of Japan [20360181].

References

1. L. Axel, L. Dougherty: Radiology. **171**(1989)841.
2. Y. Notomi, et al.: Circulation. **111**(2005)1141.
3. G. R. Sutherland, et al.: J Am Soc Echocardiogr. **7**(1994)441.
4. H. Kanai, et al.: Acoustical Science and Technology. **24**(2003)17.
5. H. Kanai, et al.: Circulation. **107**(2003)3018.
6. H. Kanai: IEEE Trans Ultrason Ferroelectr Freq Control. **52**(2005)1931.
7. H. Kanai: Ultrasound Med Biol. **35**(2009)936.
8. J. J. Zwanenburg, et al.: Am J Physiol Heart Circ Physiol. **288**(2005)H787.

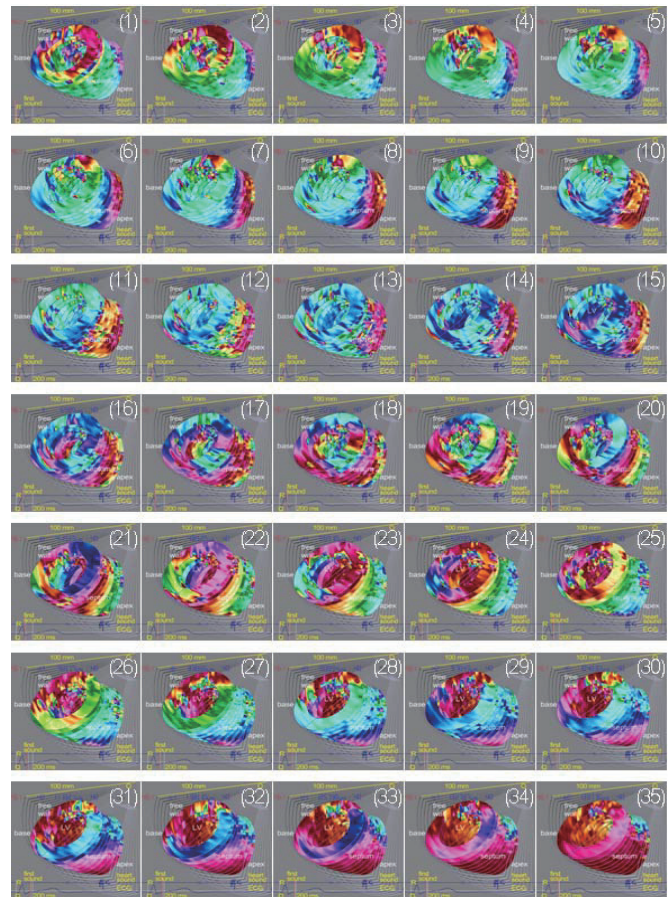


Fig. 1(1)-(35). For a healthy subject, 3D visualization of the phase distribution of 40-Hz component of the velocity waveforms at every 7.0 ms.